

Case Report: Female Intimate Surgery

Author:

Dr Gabriel Femopase (Cordoba National University - Argentina)

Patient Details

Patient: young 19 year old, nulliparous, menarche at age 12, early sexual intercourse at age 17.

Reason for consultation: dyspareunia, aesthetic improvement.

Physical Examination: On physical examination the patient presents hypertrophy of both labia minora, mucocutaneous paraclitoridian bilateral fold. In the Introit, vaginal hymeneal hypertrophy of caruncles at 12 o'clock, which protrudes outwardly is observed.

Gyneacological Examination: normal, exfoliative cytology according to age, normal ultrasound study. Score of sexual satisfaction has low values in desire, arousal, lubrication, orgasm, satisfaction, and significantly high pain and discomfort.

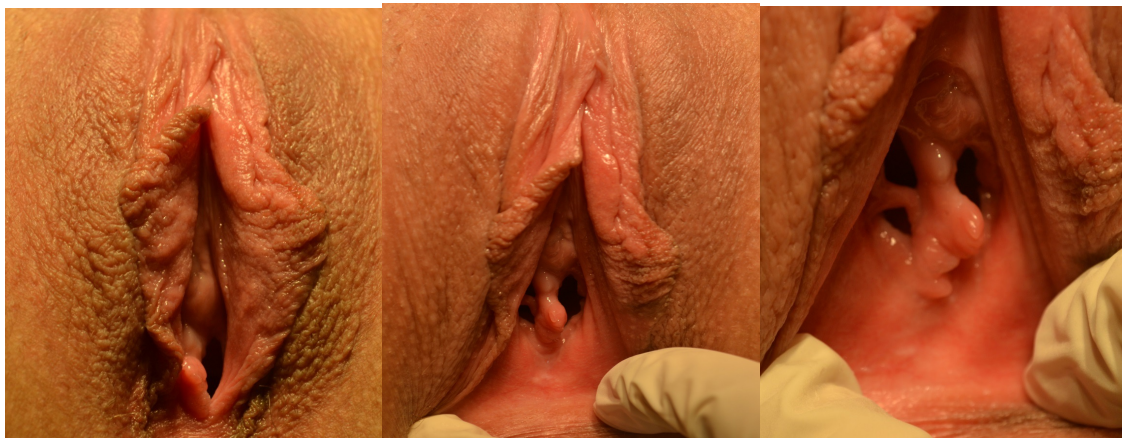

Fig. 1: Pre procedure

Procedure

Procedure: Patient is placed in the operating room under spinal anesthesia and in gynecological position. We performed FemiLift procedure and External Rejuvenation using Alma CO2 Laser and dedicated handpieces. For the hypertrophy of both labia minora, we used the vaporization effect on mucocutaneous folds setting the laser on

Dr Gabriel Femopase (Universidad Catolica de Cordoba - Argentina)

Case Report: Female Intimate Surgery

15W. Once the anatomical correction is achieved, we proceed to complete with a suture using polyglactin 910 absorbable 6/0 and 5/0. Finally we trimmed the hypertrophic caruncula using focused laser at 12W.

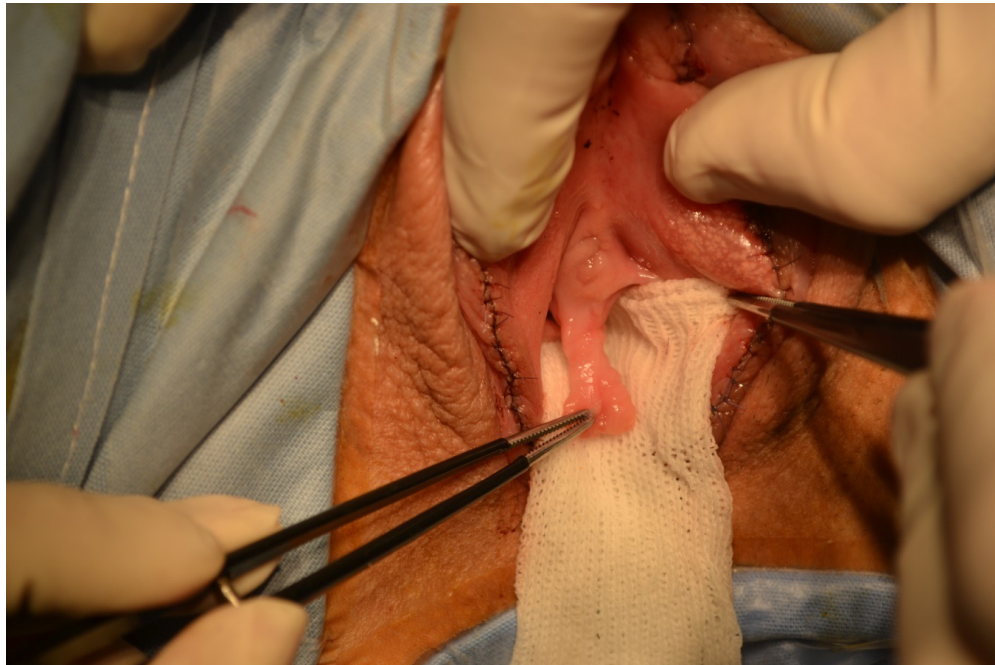


Fig 2: Surgery

Total surgical time was 80 minutes with no complications.

Post-operative indications: we recommend use of ice locally and hygiene with neutral pH soap. Patient should abstain from sex for six weeks due to external sutures. Control is done at 7 and 40 days.

Case Report: Female Intimate Surgery

